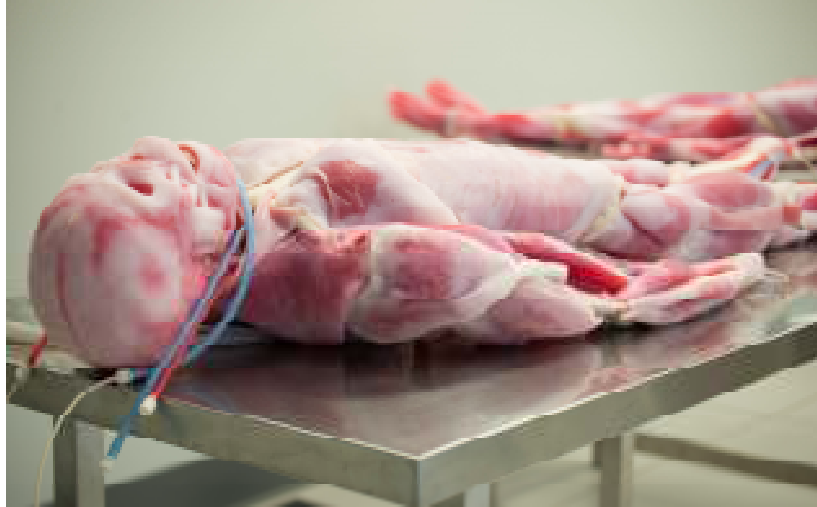
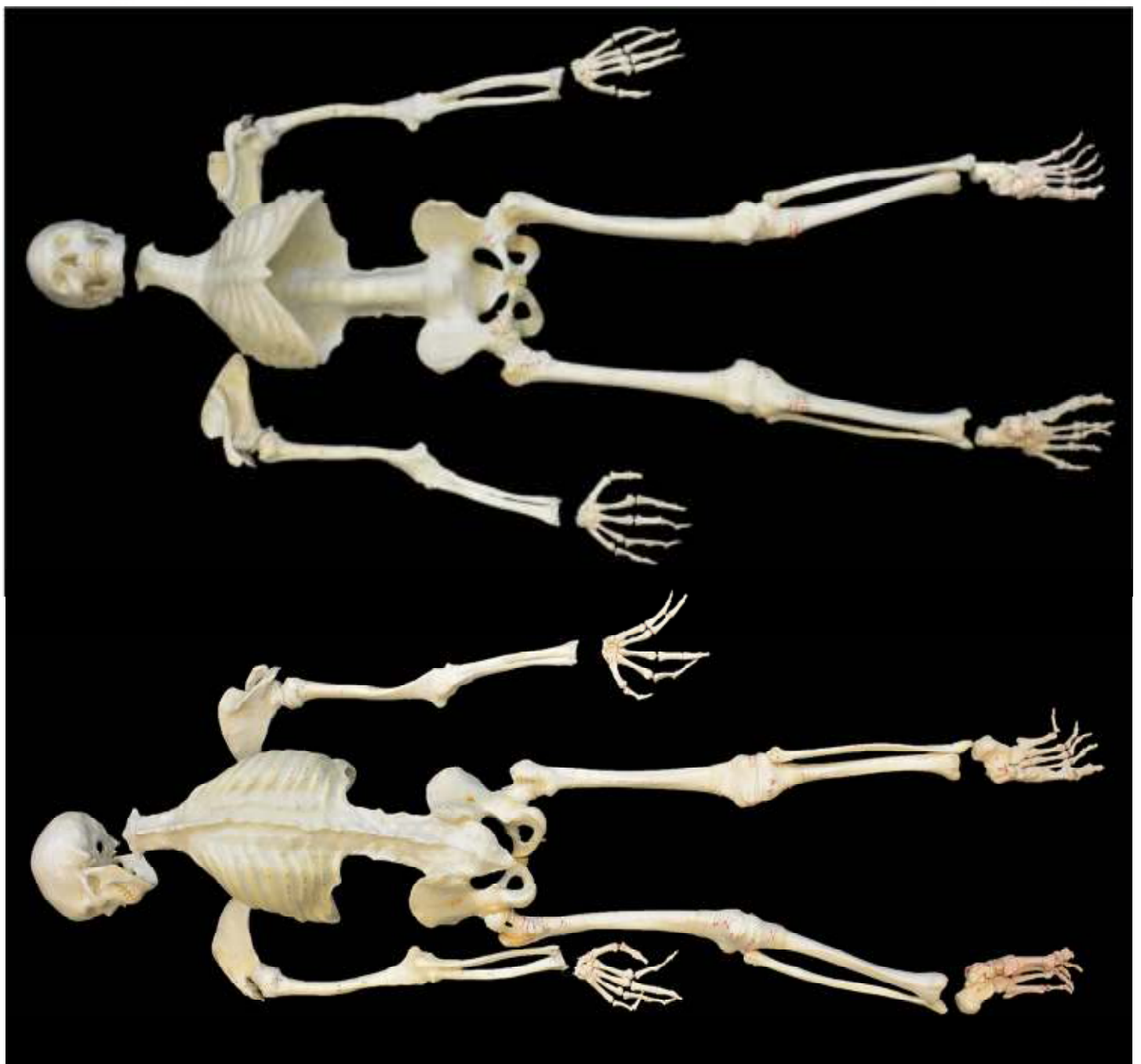
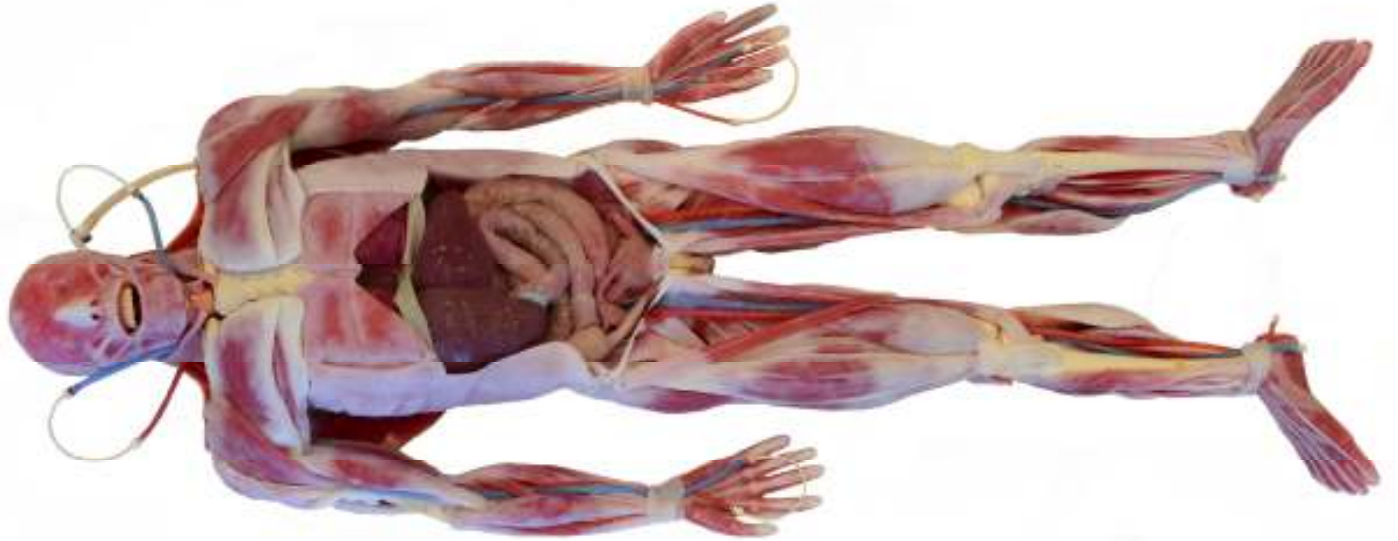

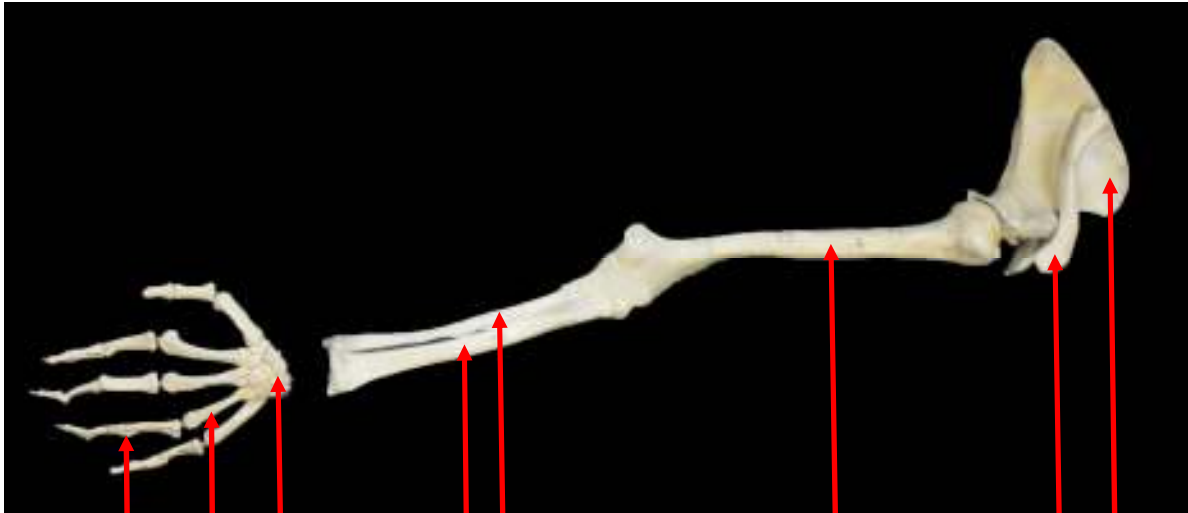
**SynDaver<sup>TM</sup> Labs**

**Synthetic Human  
Anatomy Diagram**

# SynDaver Synthetic Human




# ARM

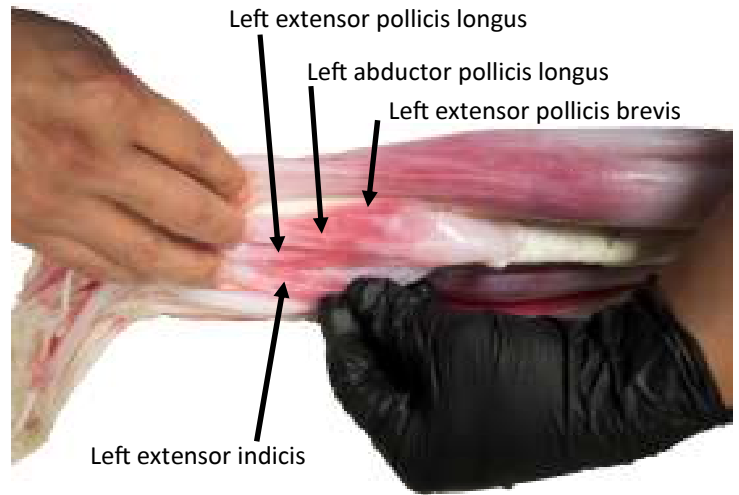


Phalanges  
Metacarpals  
Carpals  
Radius  
Ulna  
Humerus  
Clavical  
Scapula

Left flexor digitorum superficialis



Left Brachioradialis

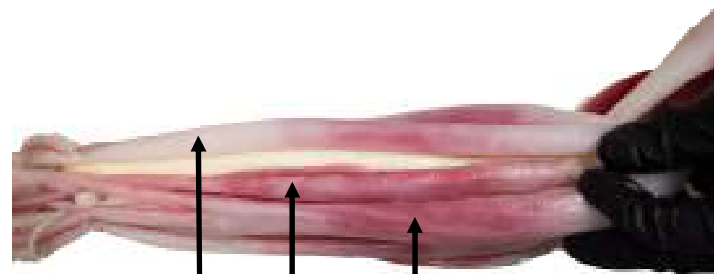


Left extensor pollicis longus

Left abductor pollicis longus

Left extensor pollicis brevis

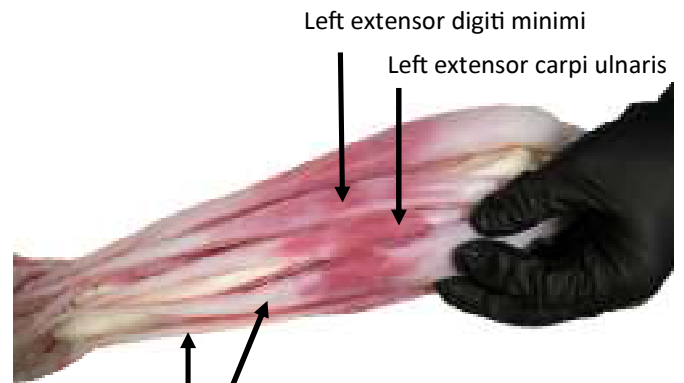
Left extensor indicis



Left extensor digitorum

Left extensor carpi radialis Brevis

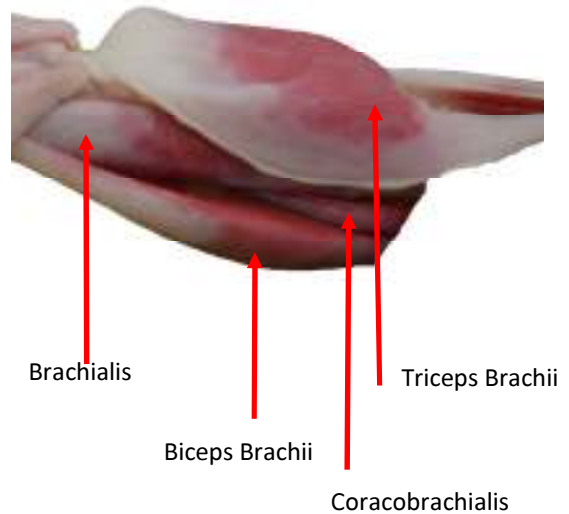
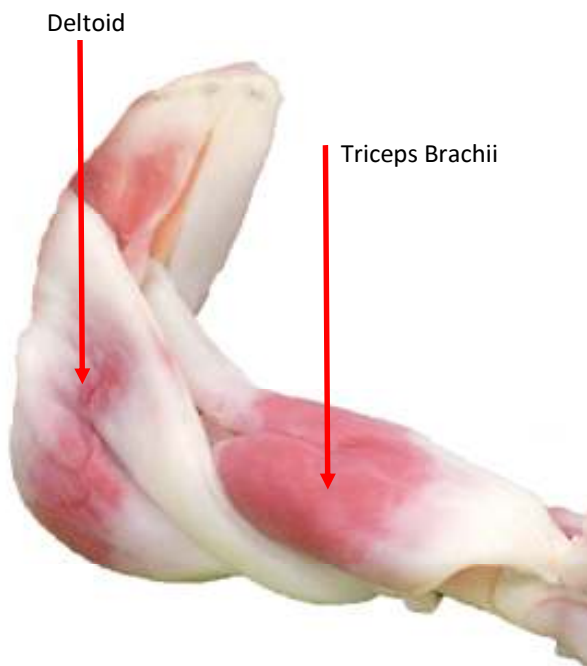
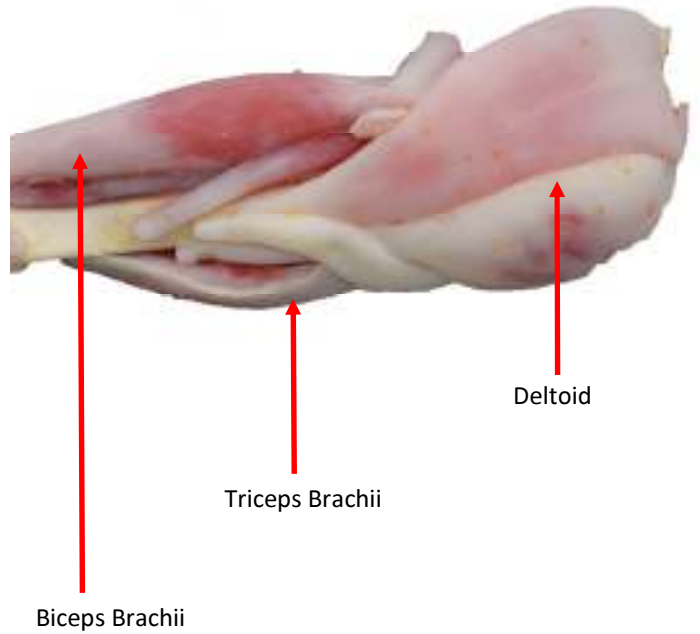
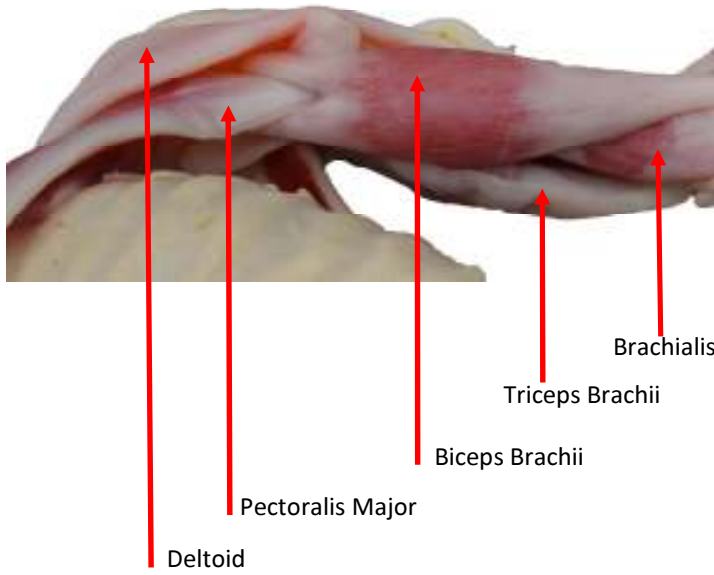
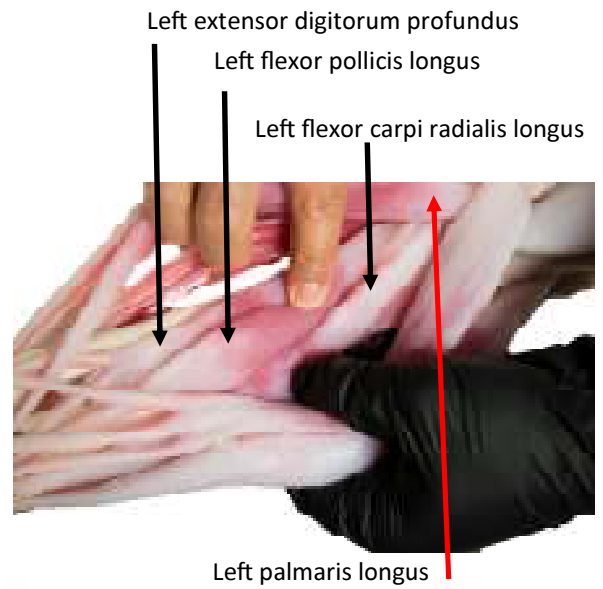
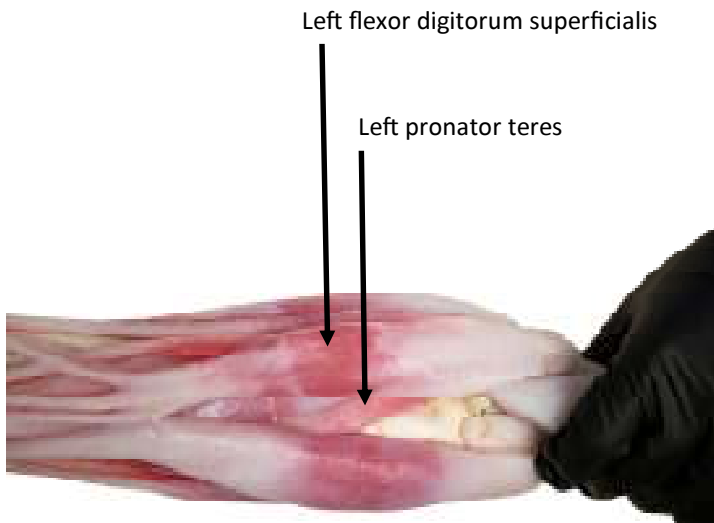
Left extensor carpi radialis longus



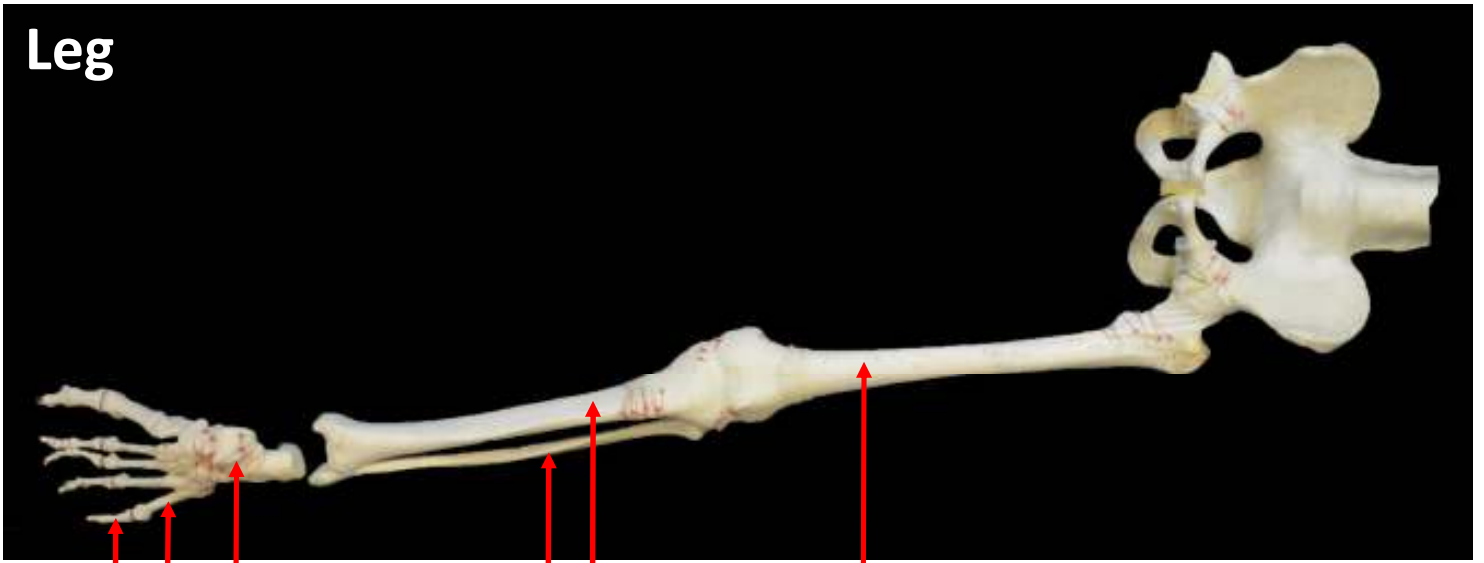Left extensor digiti minimi

Left extensor carpi ulnaris

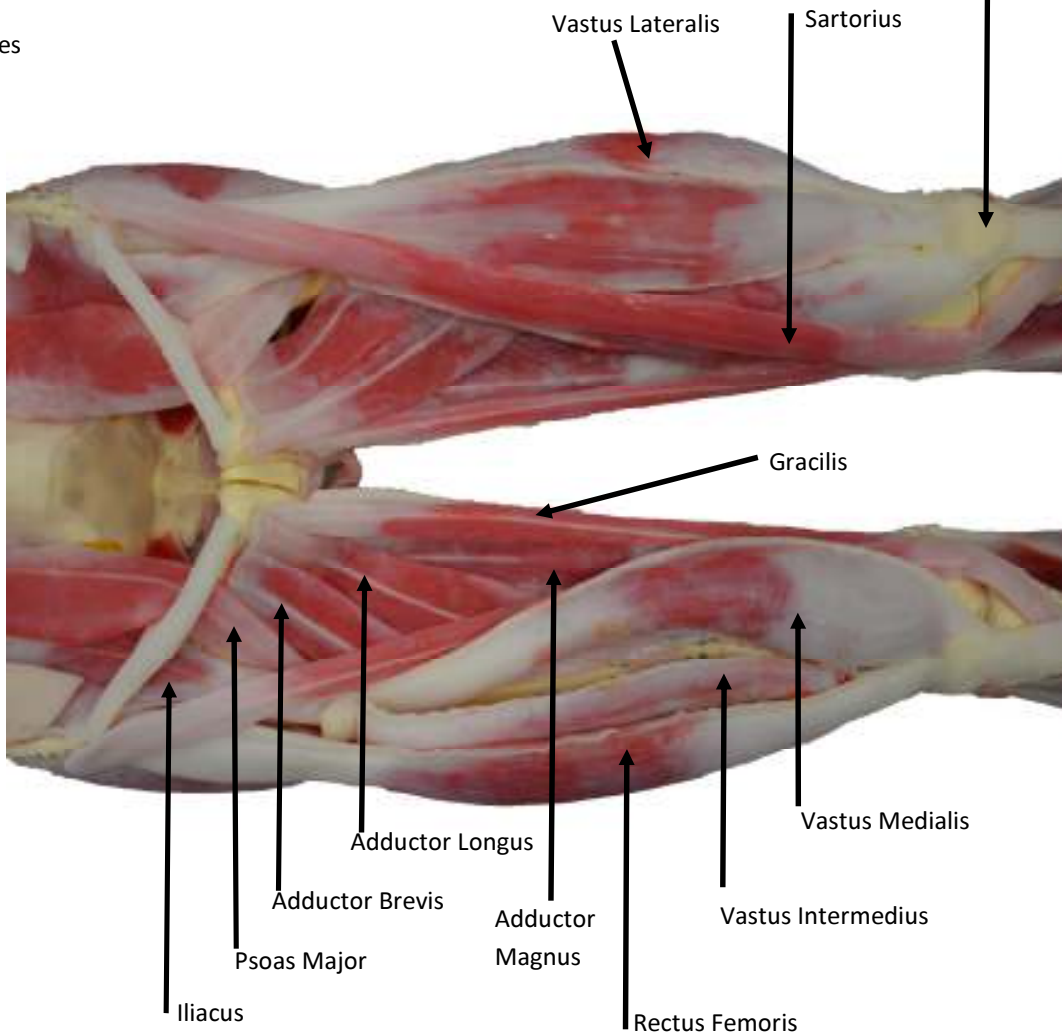
Left flexor carpi ulnaris



# Leg



phalanges  
Metatarsals  
Tarsals  
Fibula  
Tibia  
Femur  
Patella



Vastus Lateralis  
Sartorius

Gracilis

Adductor Longus

Adductor Brevis

Adductor Magnus

Vastus Medialis

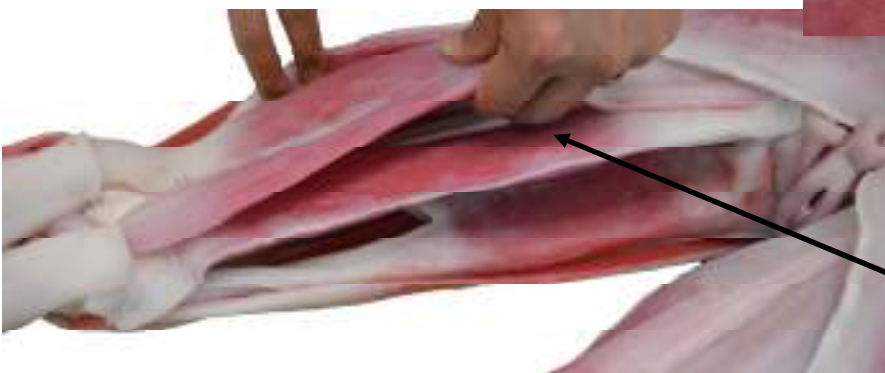
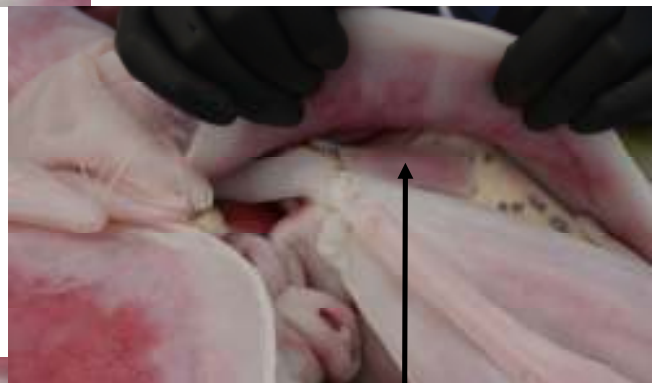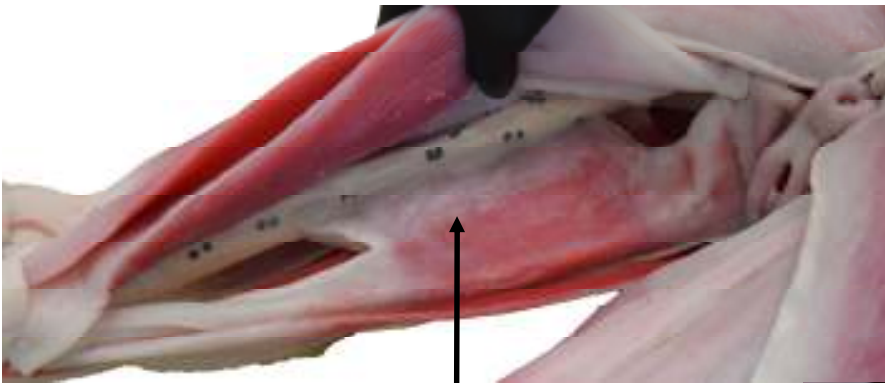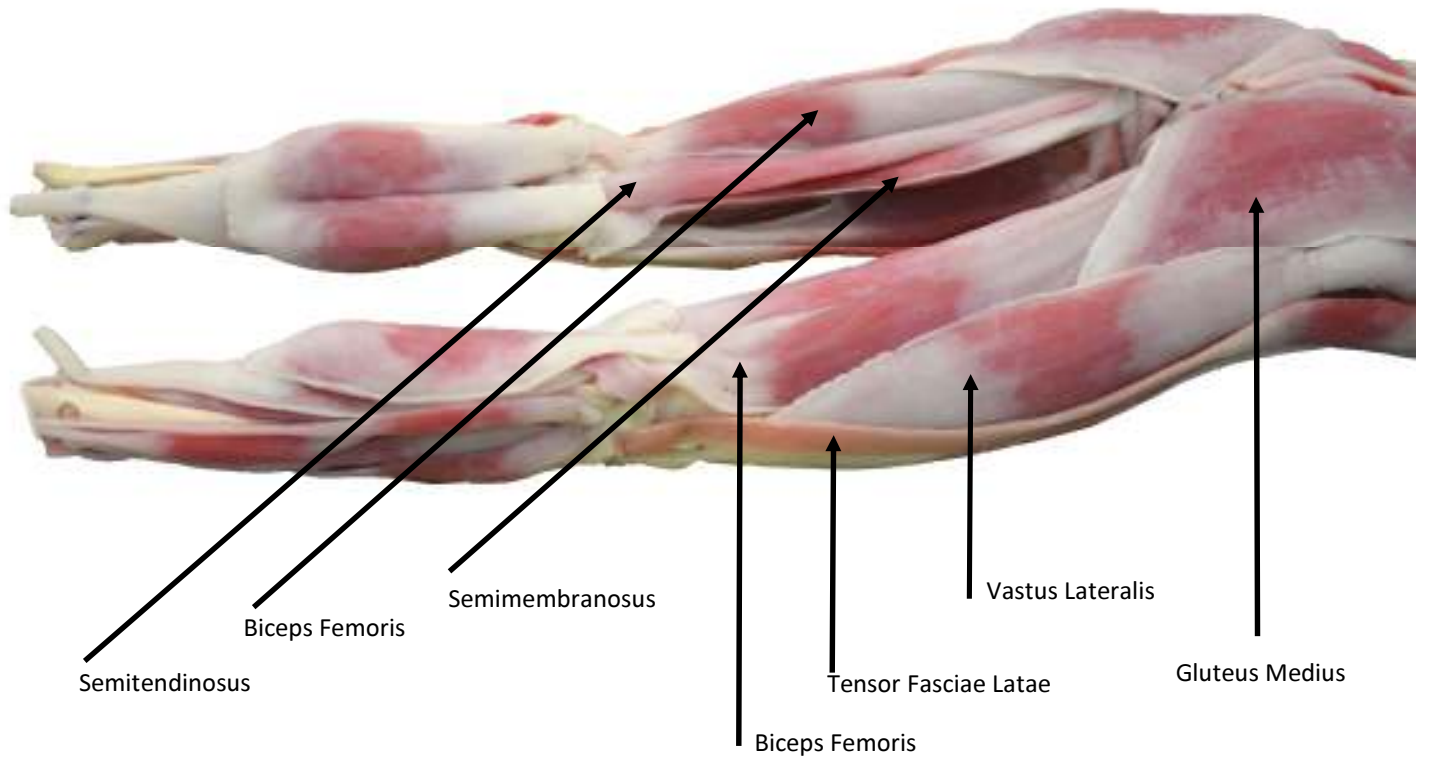
Vastus Intermedius

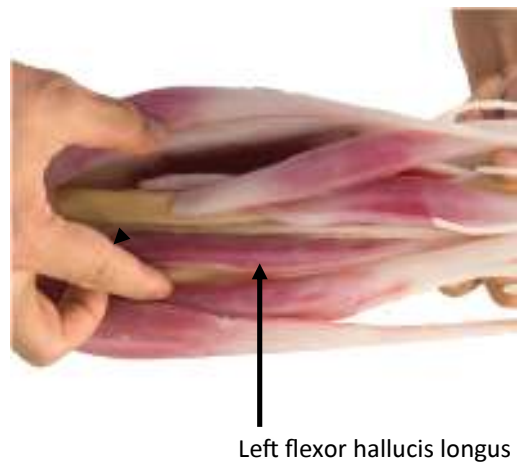
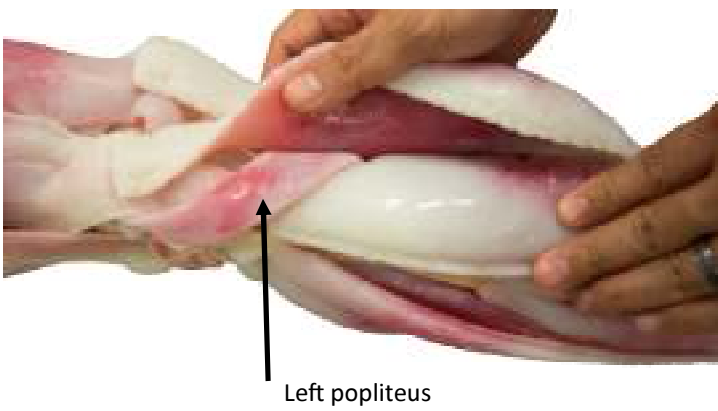
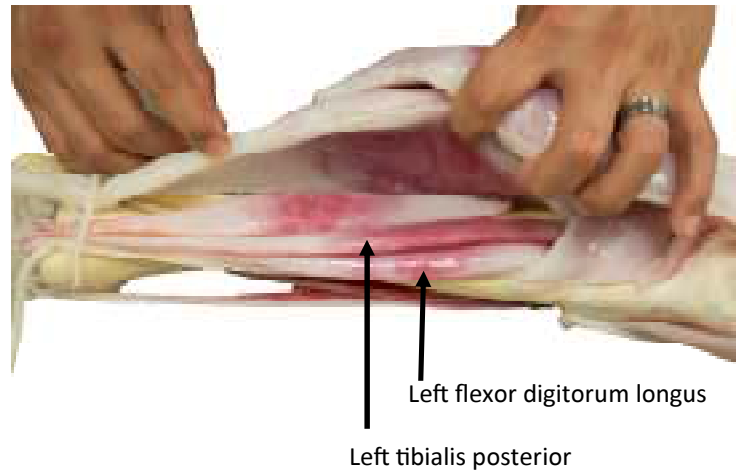
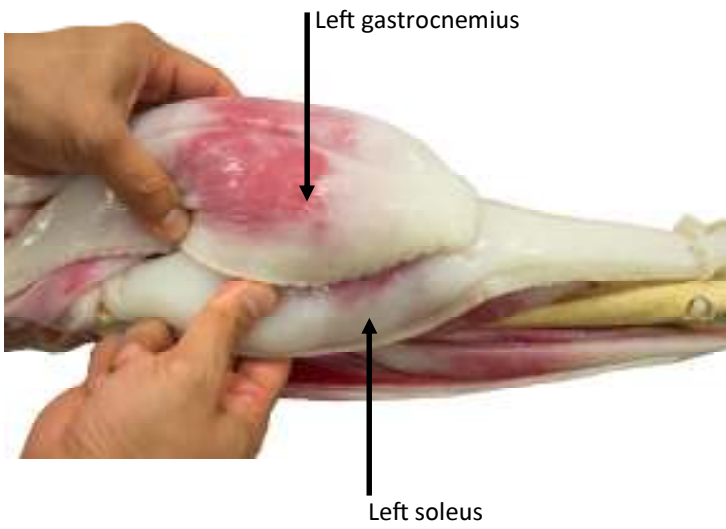
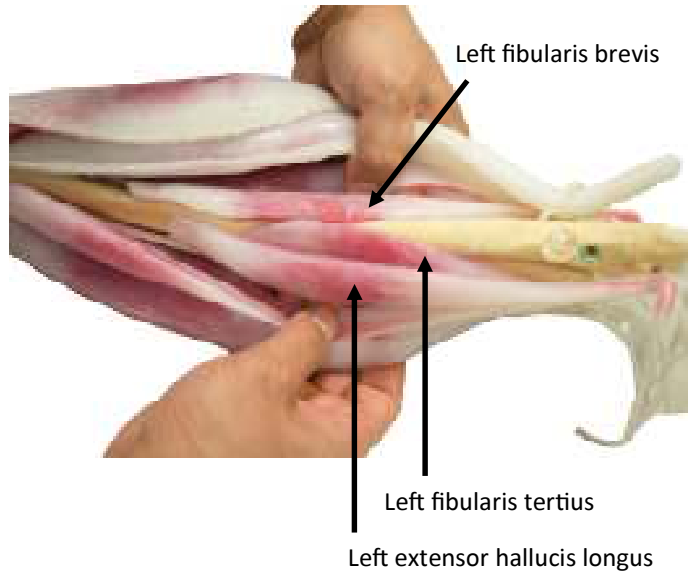
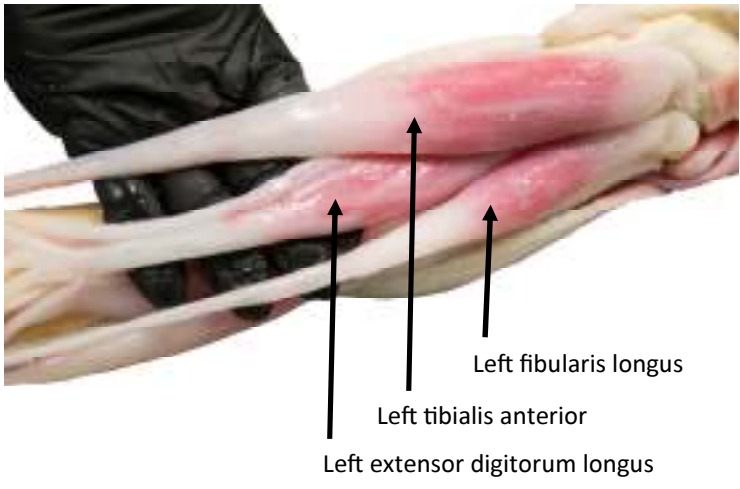
Rectus Femoris

Iliacus

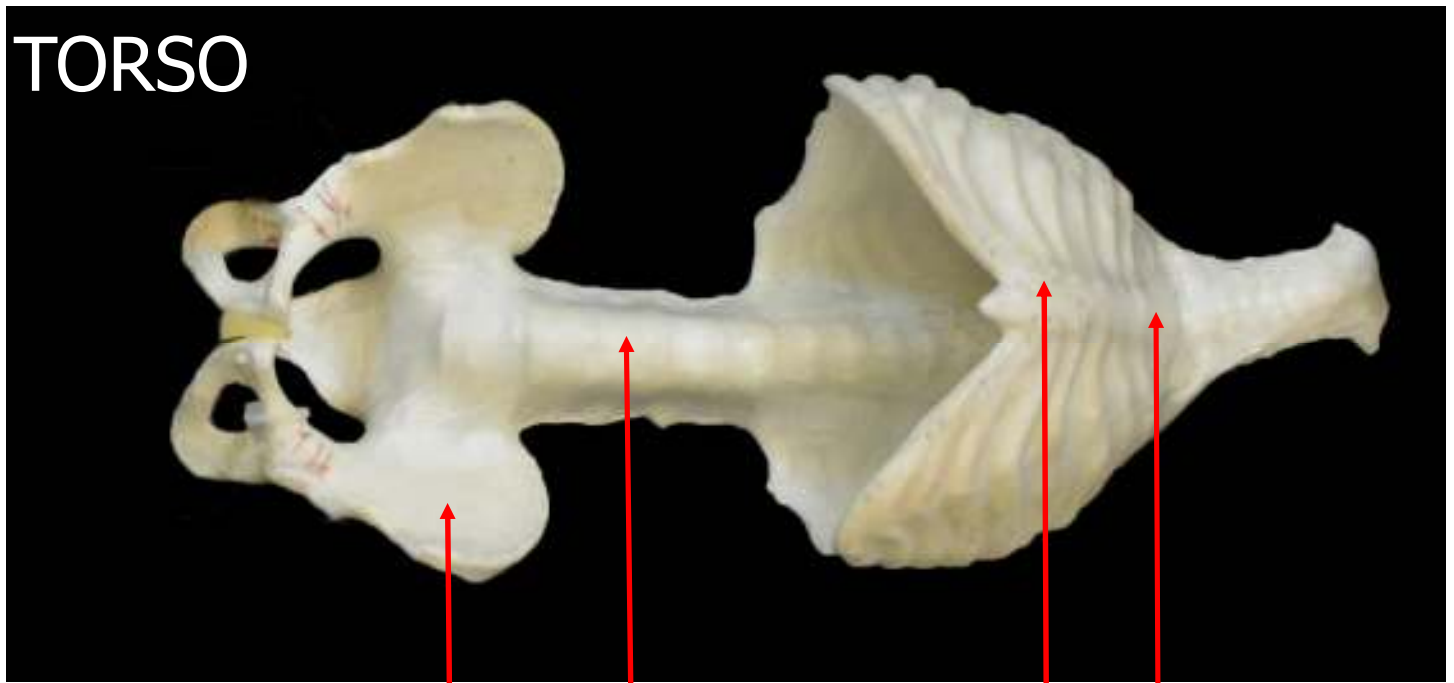
Psoas Major







# TORSO




Pelvis

Spine

Sternum

Manubrium



Coccyx

Sacrum

Lumbar Vertebrae

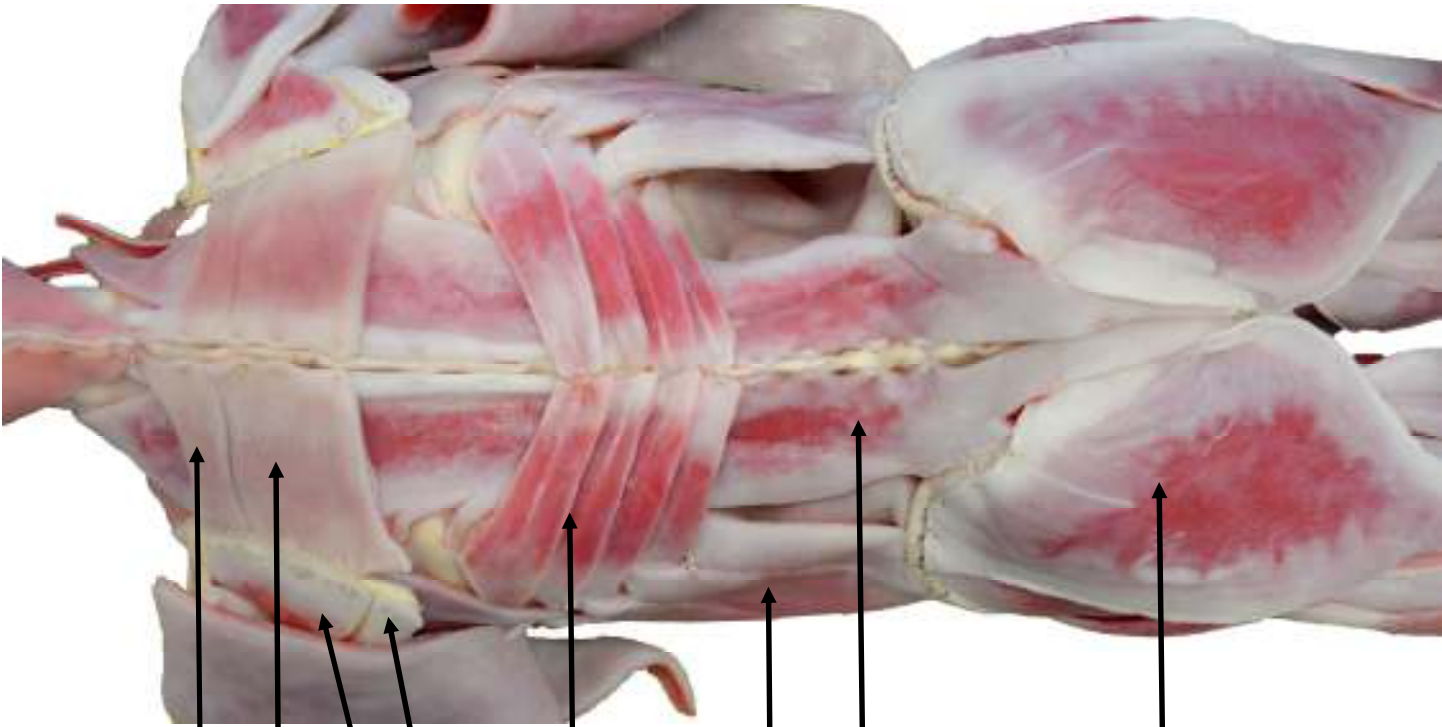
Floating Ribs

True Ribs

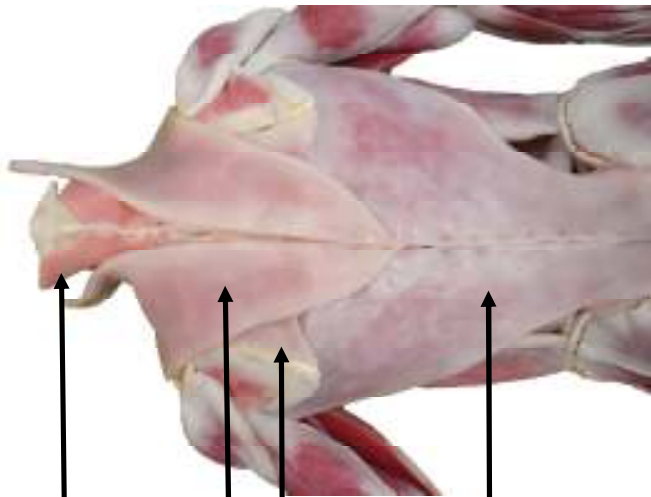
Thoracic Vertebrae

Cervical Vertebrae

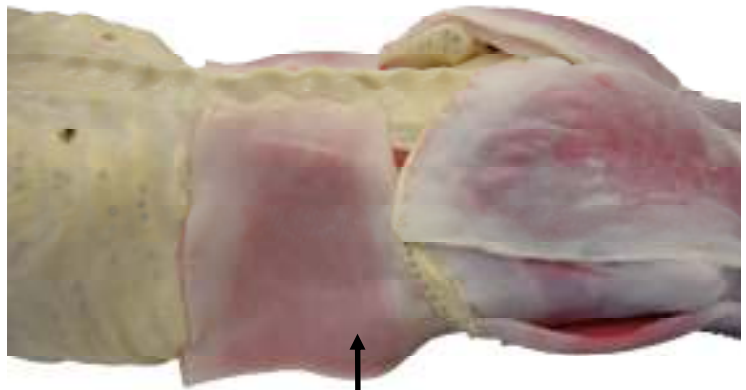




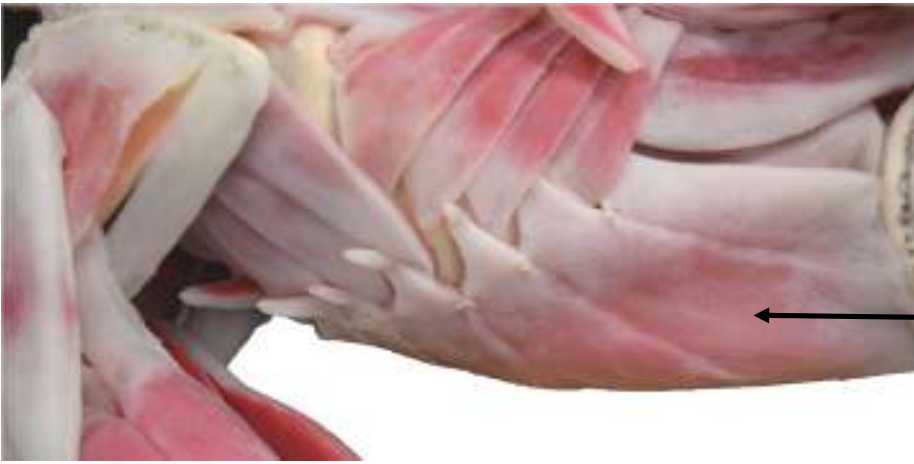Rhomboid Minor  
 Rhomboid Major  
 Teres  
 Infraspinatus  
 Serratus Posterior inferior  
 Erector Spinae  
 External Oblique  
 Gluteus Maximus



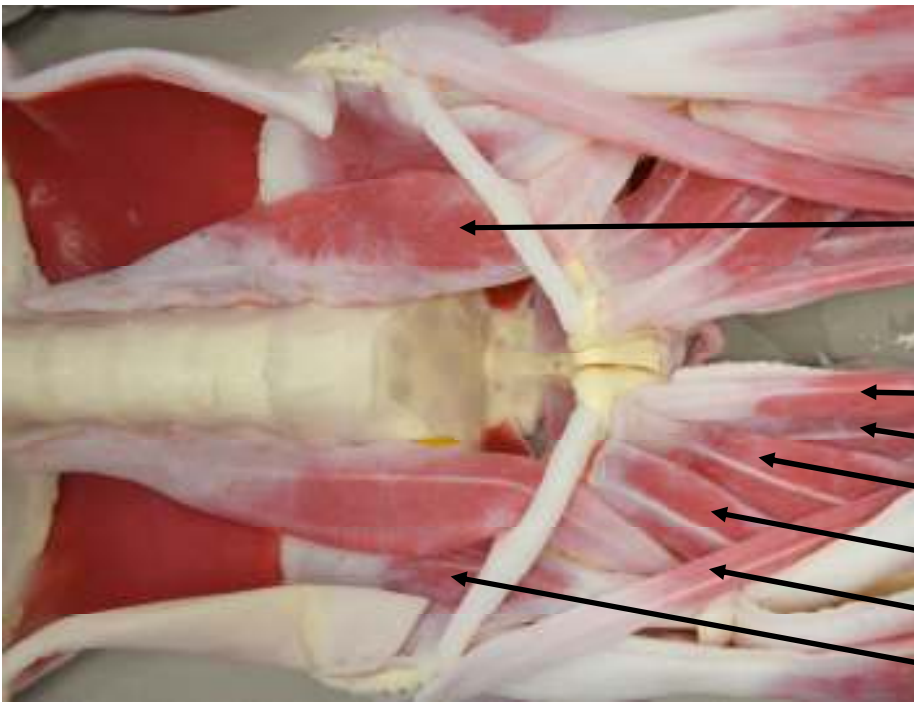
Splenius Capitis  
 Trapezius  
 Rhomboid Major  
 Latissimus Dorsi



Transversus Abdominis &  
 Internal Oblique



External Oblique



Psoas Major

Gracilis

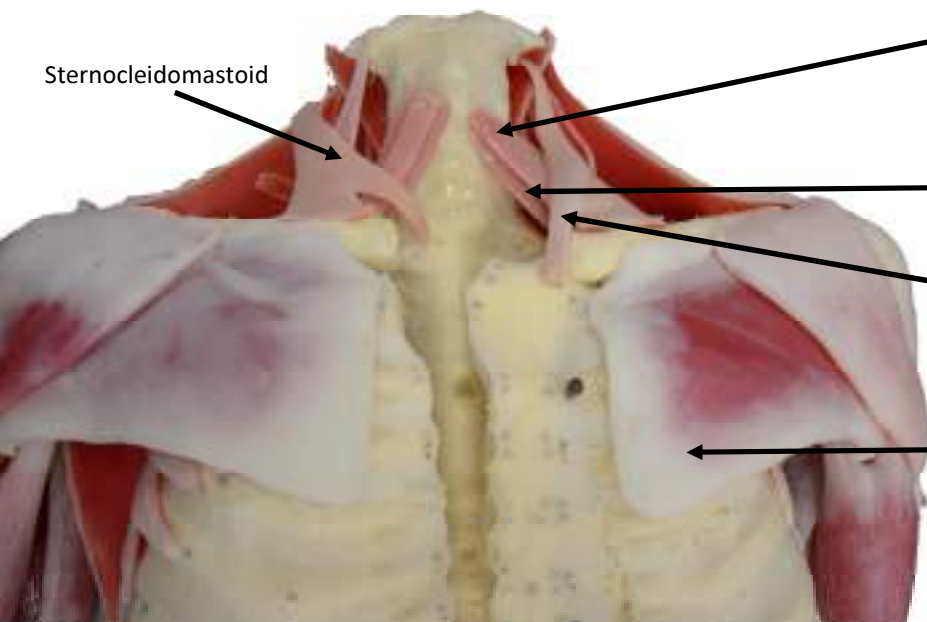
Adductor Magnus

Adductor Longus

Adductor Brevis

Sartorius

Iliacus



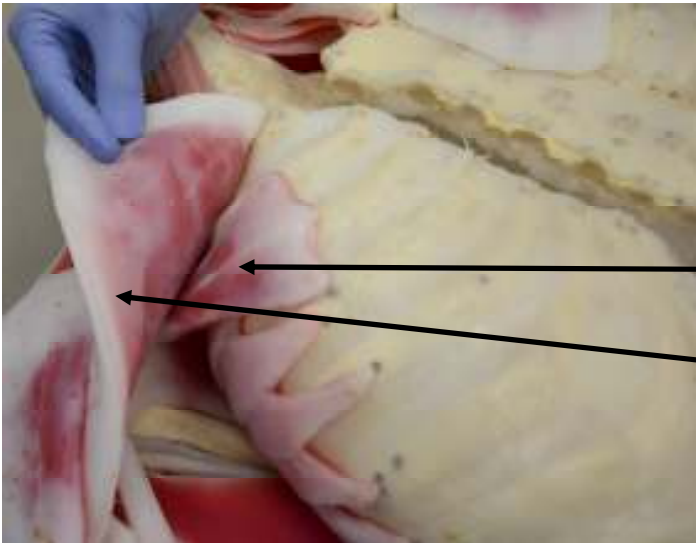
Sternocleidomastoid

Omohyoid

Sternohyoid

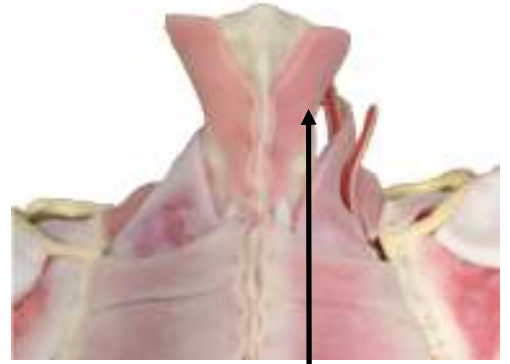
Sternocleidomastoid

Pectoralis Major

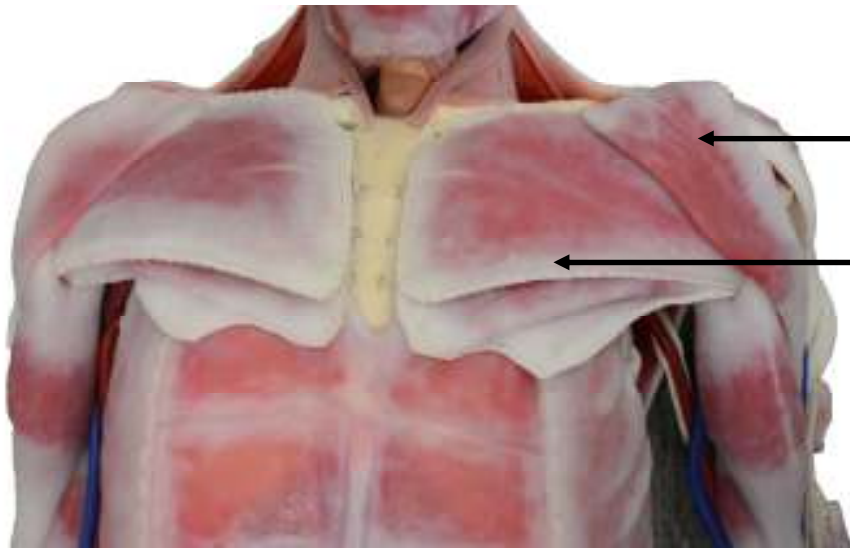


Pectoralis Minor

Pectoralis Major

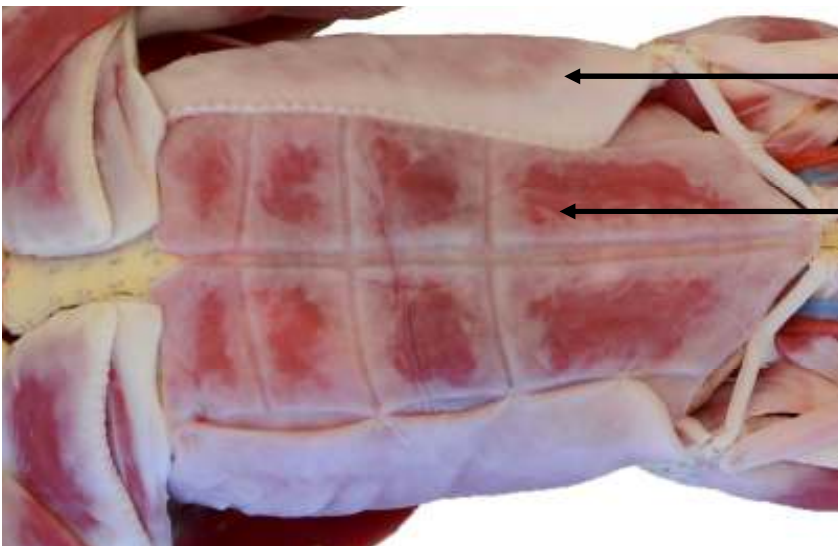


Splenius Capitis



Deltoid

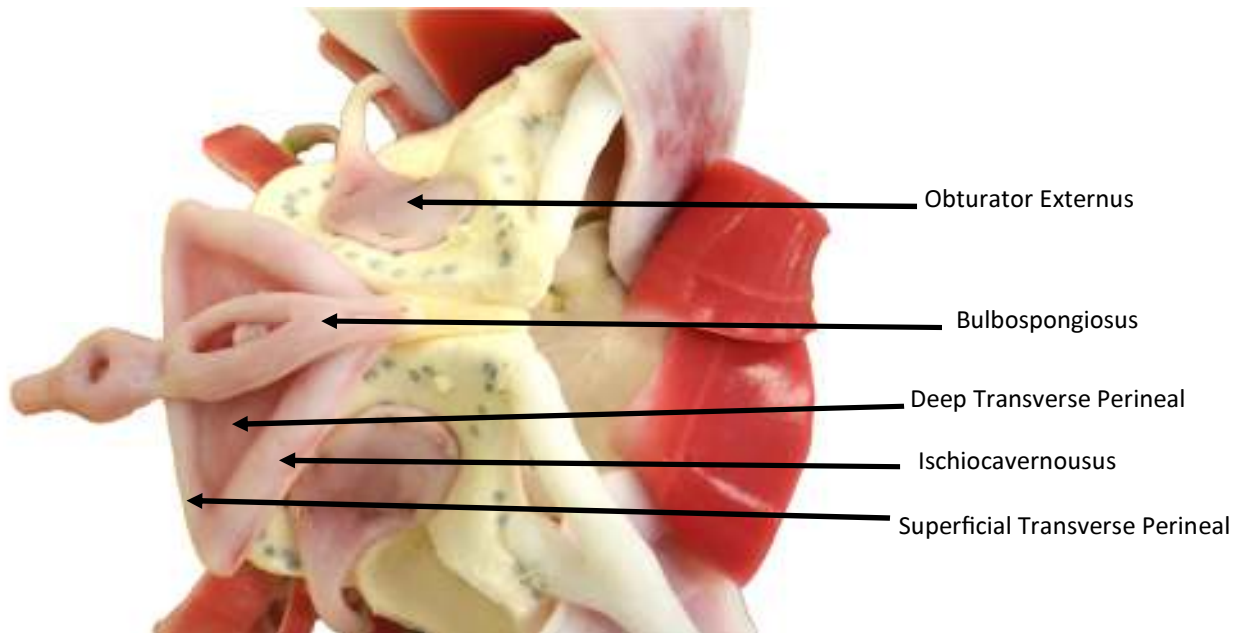
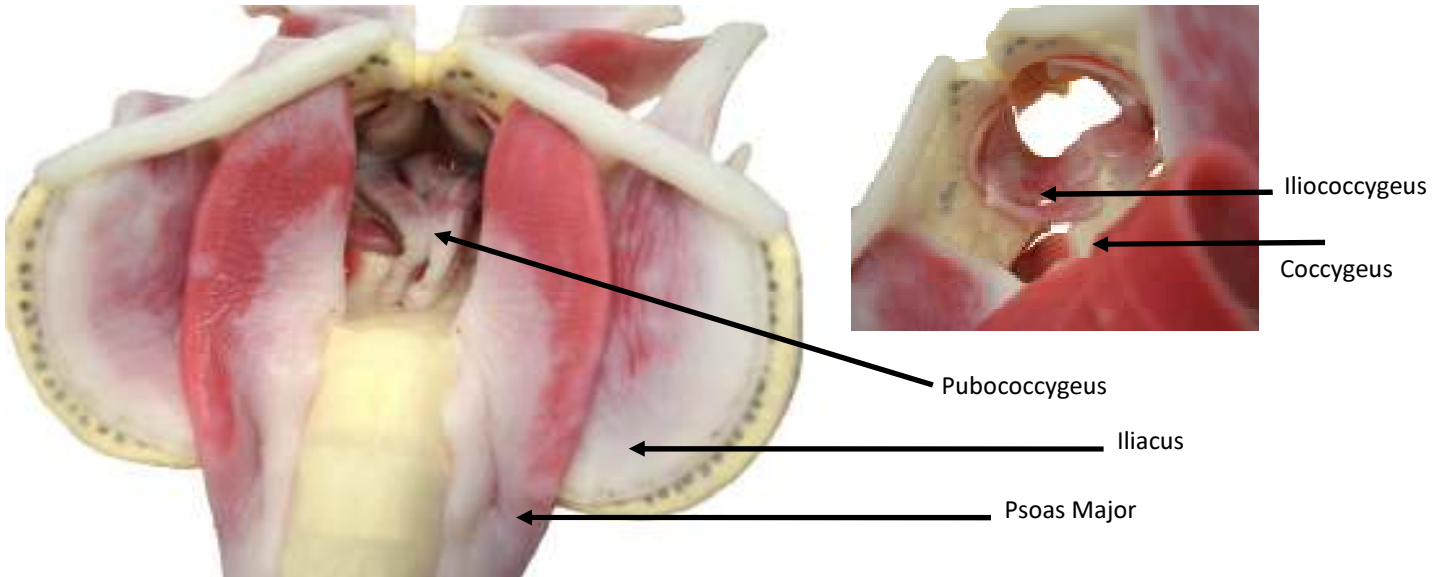
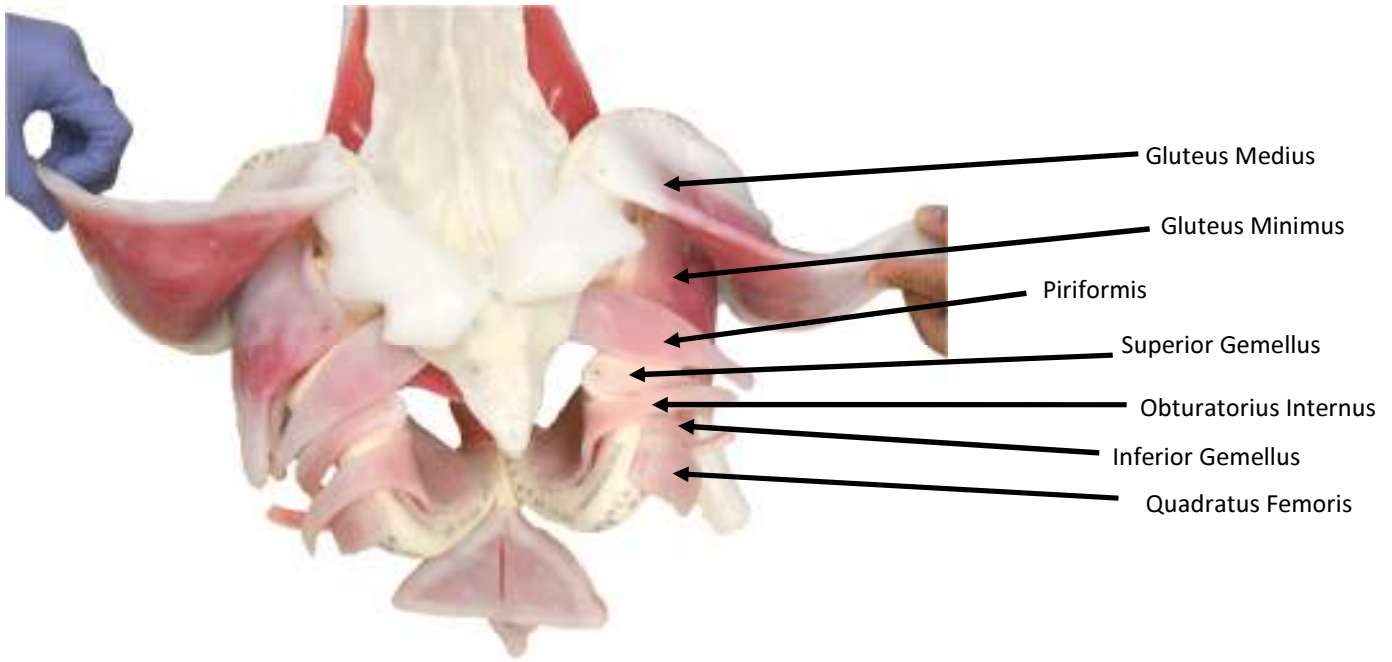
Pectoralis Major



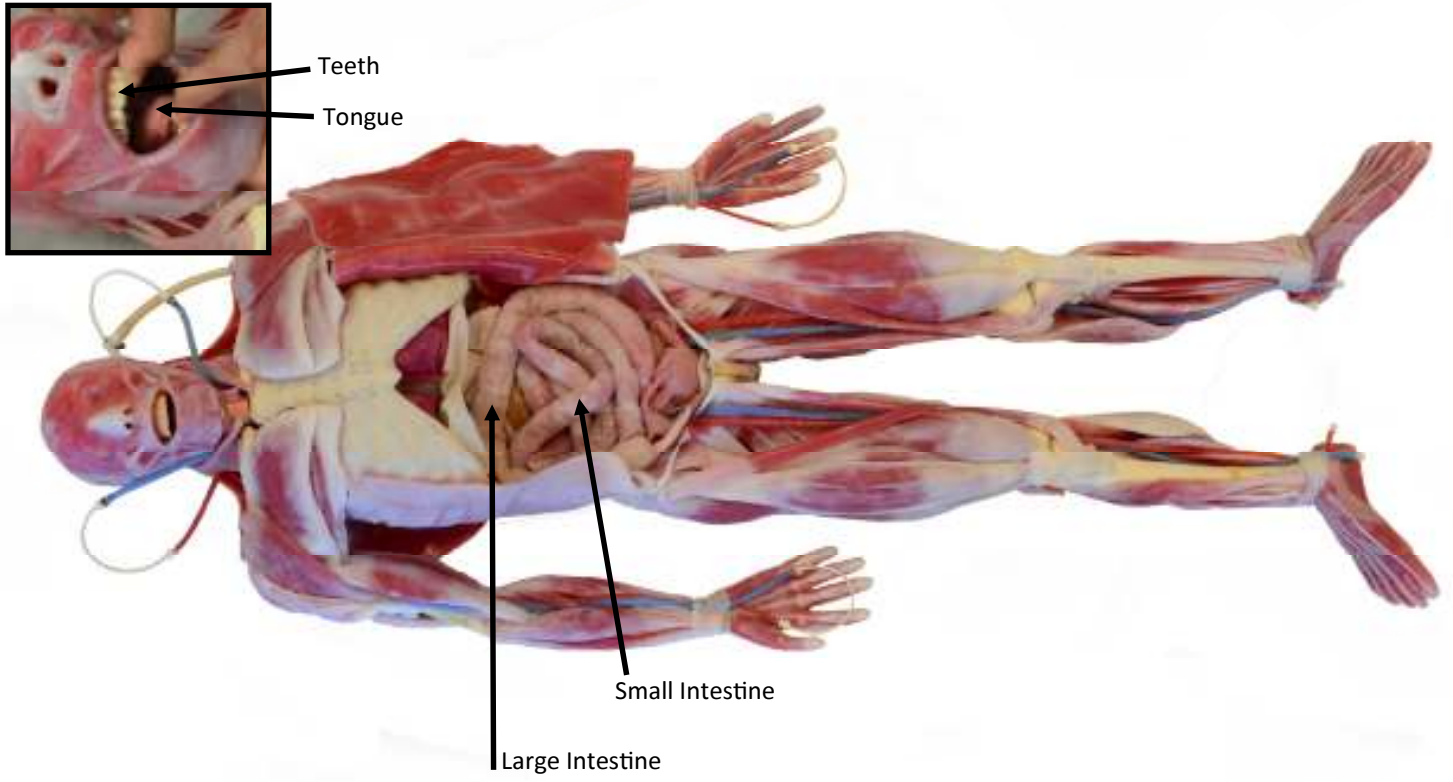
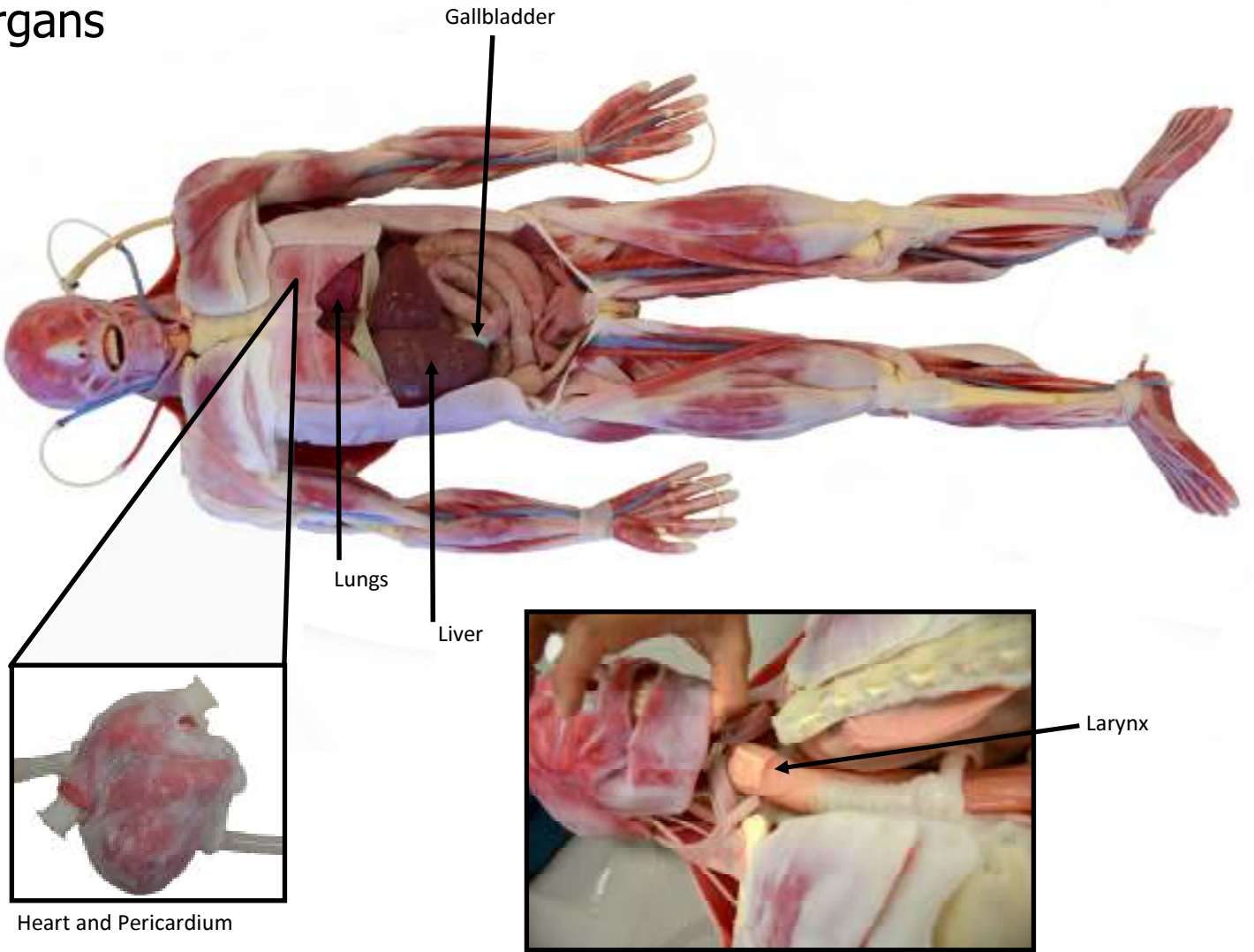
External Oblique

Rectus Abdominis

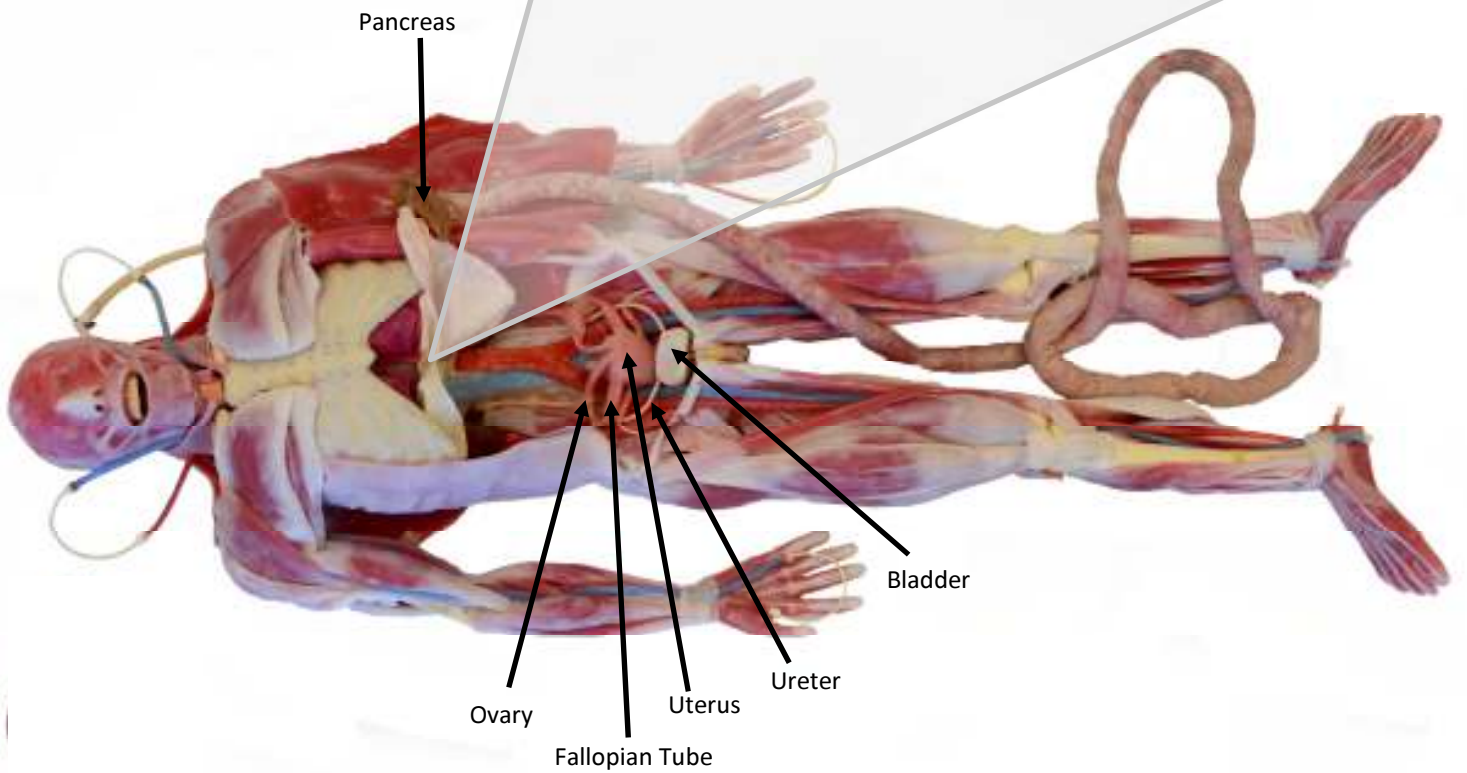
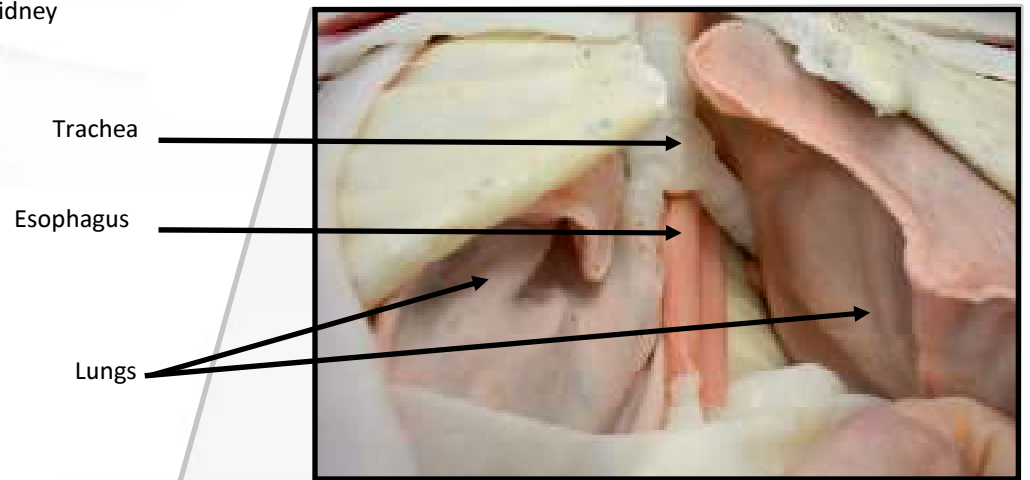
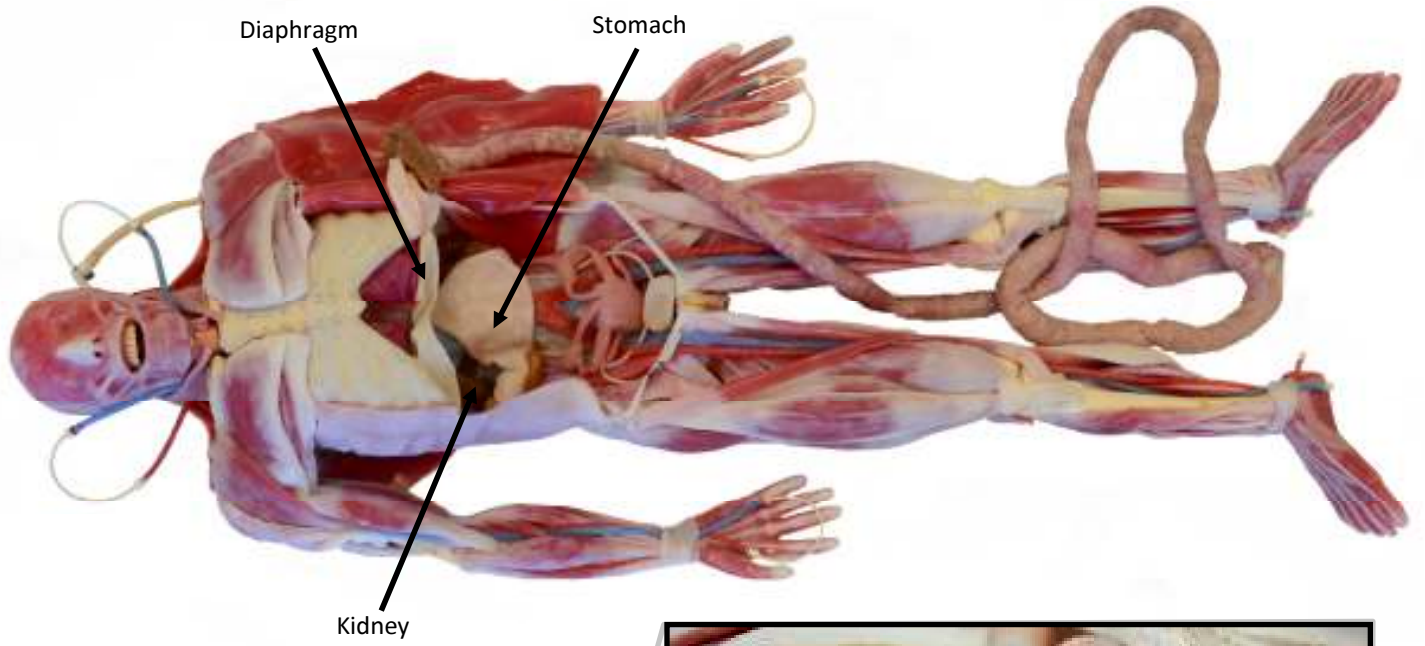




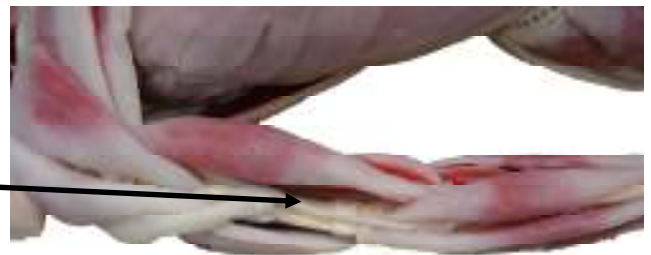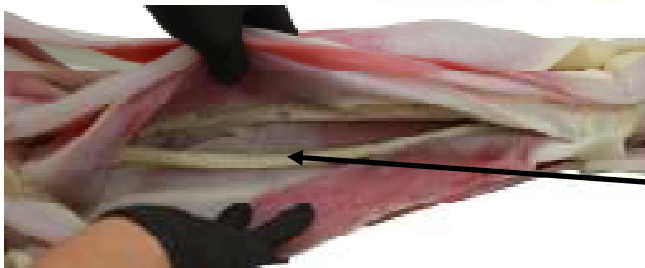
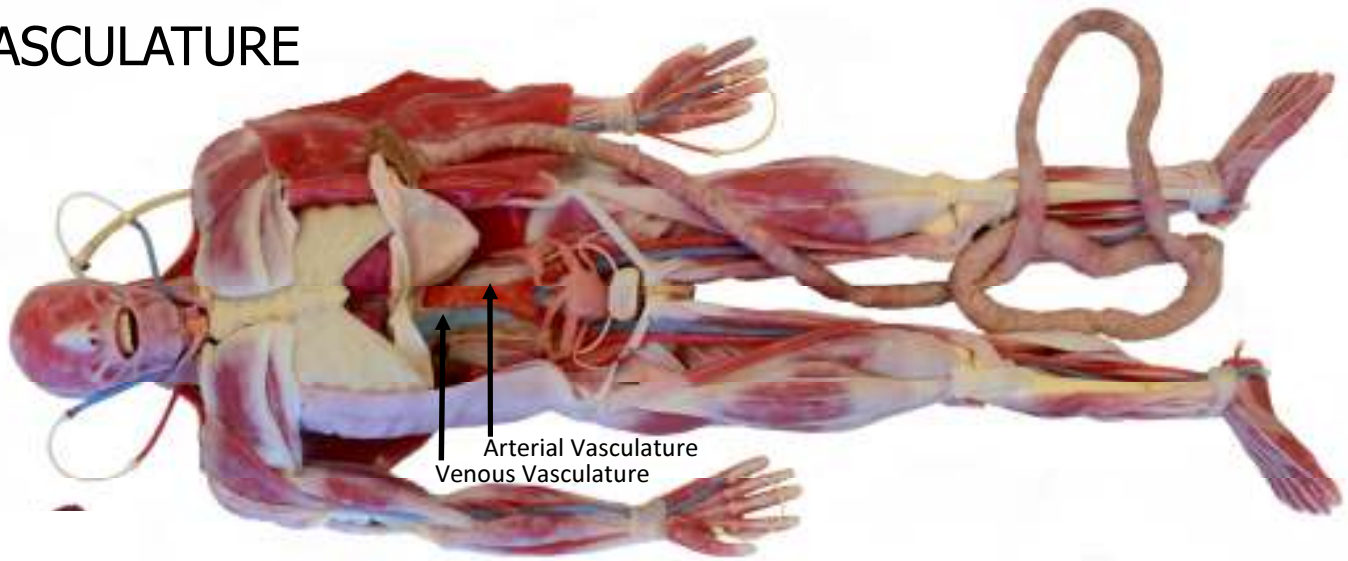
# Organs





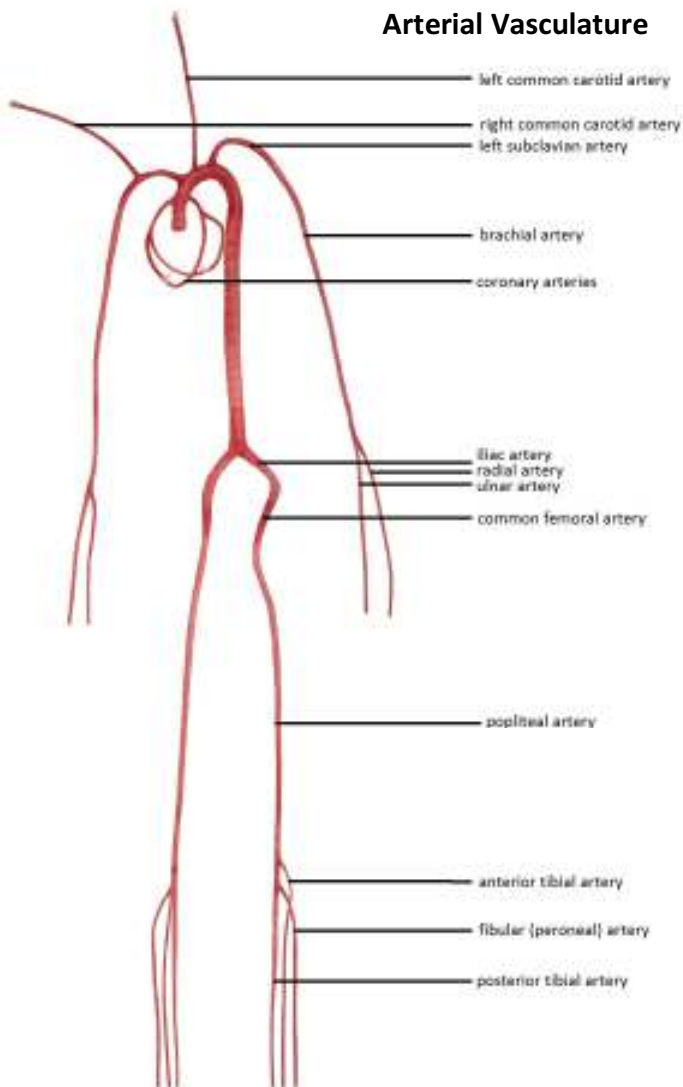


# VASCULATURE



Nerves

## Arterial Vasculature



## Venous Vasculature

